

# Left Ventricular Noncompaction And Pregnancy

---

Radha J. Sarma, MD, FACC, FACP, FAHA.

Associate Professor of Clinical Medicine.

USC Keck school of Medicine.

Director of Cardiac Stress Lab.

Associate Director Echocardiography Lab.

LAC+USC Medical Center, Los Angeles, C.A. USA

February 27, 2010

Valencia, Spain

*No Financial Disclosures for this presentation*

# Introduction

# Normal Morphology of LV

Normal Left Ventricle has smooth endocardium and compact myocardium.

“Discrete muscle bundles, more than 2 mm in diameter, that stood out against the background of the left ventricular endocardium” have been reported in 68% of normal hearts but are **virtually always three or less in number.**

# Normal Variants In LV

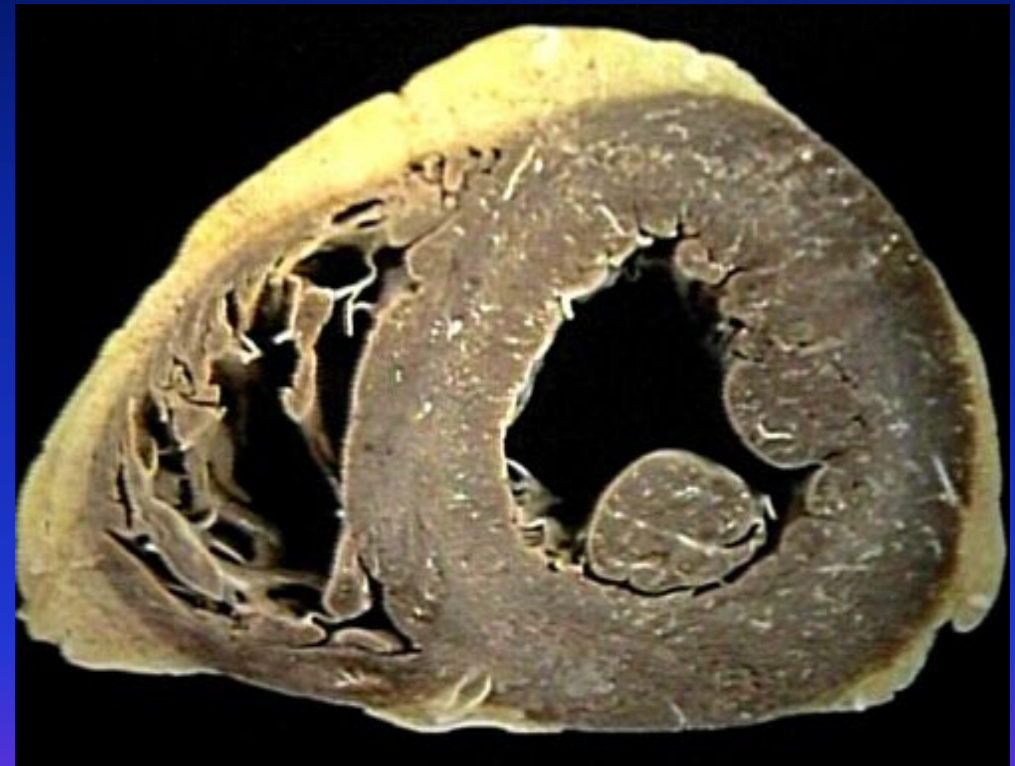Normal left ventricle may contain:

False tendons

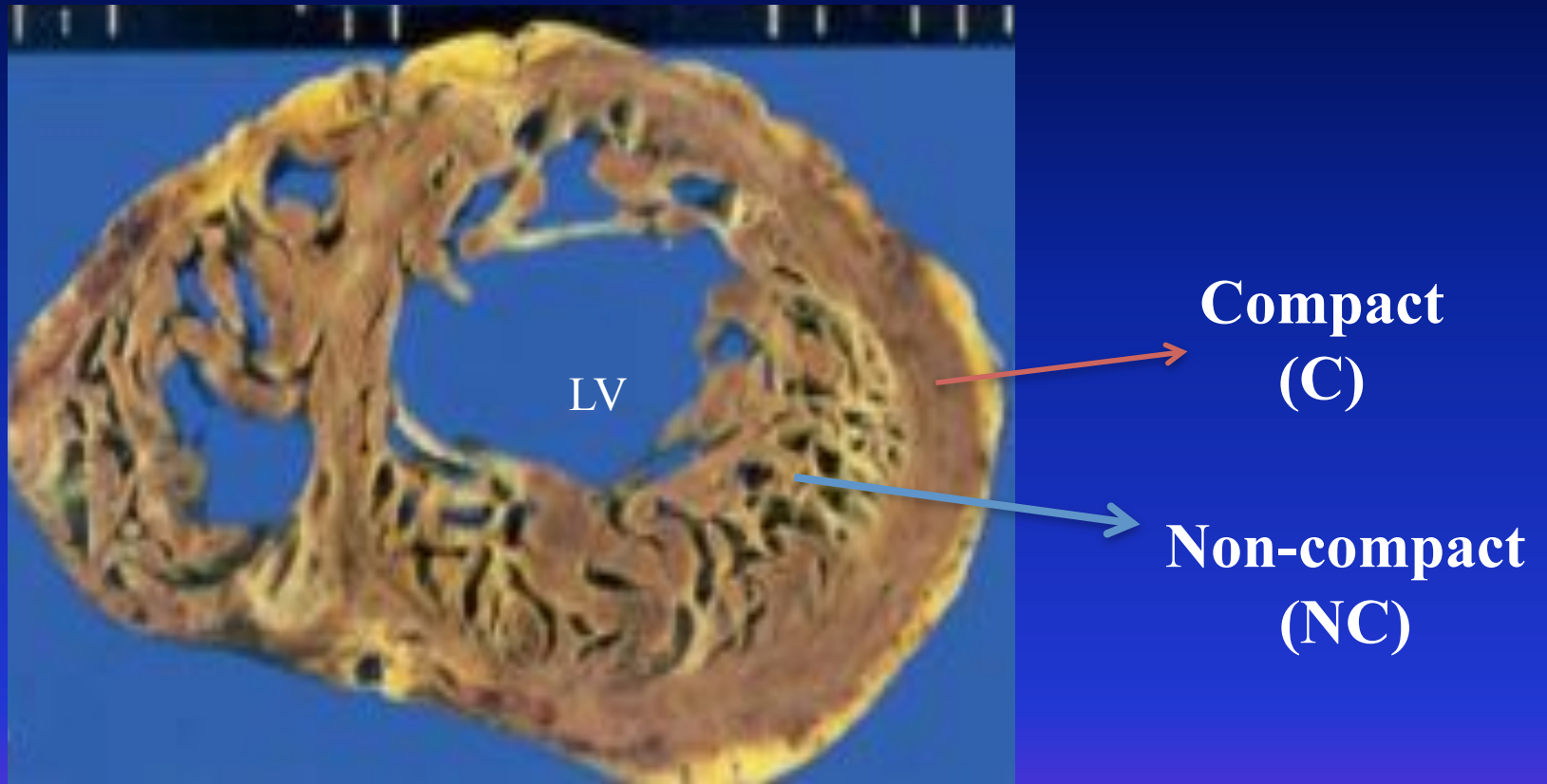
Muscular trabeculations

Intertrabecular recesses

These normal trabeculations never produce a discrete trabecular layer rivalling in thickness of the compact layer.



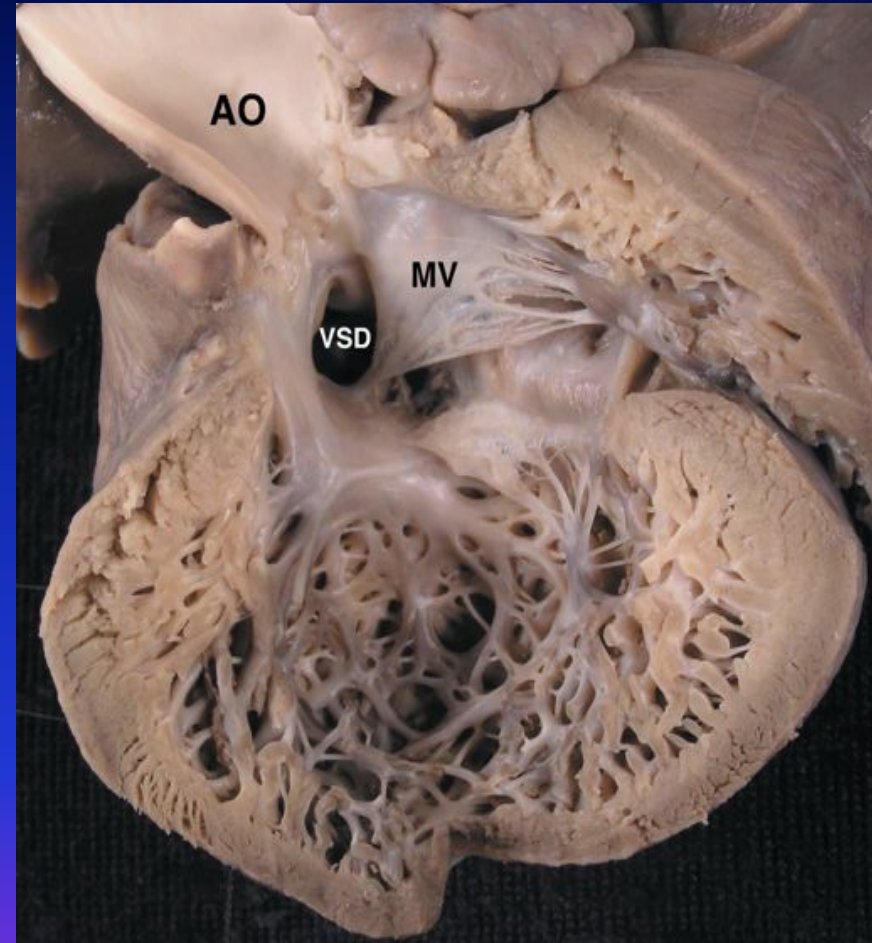
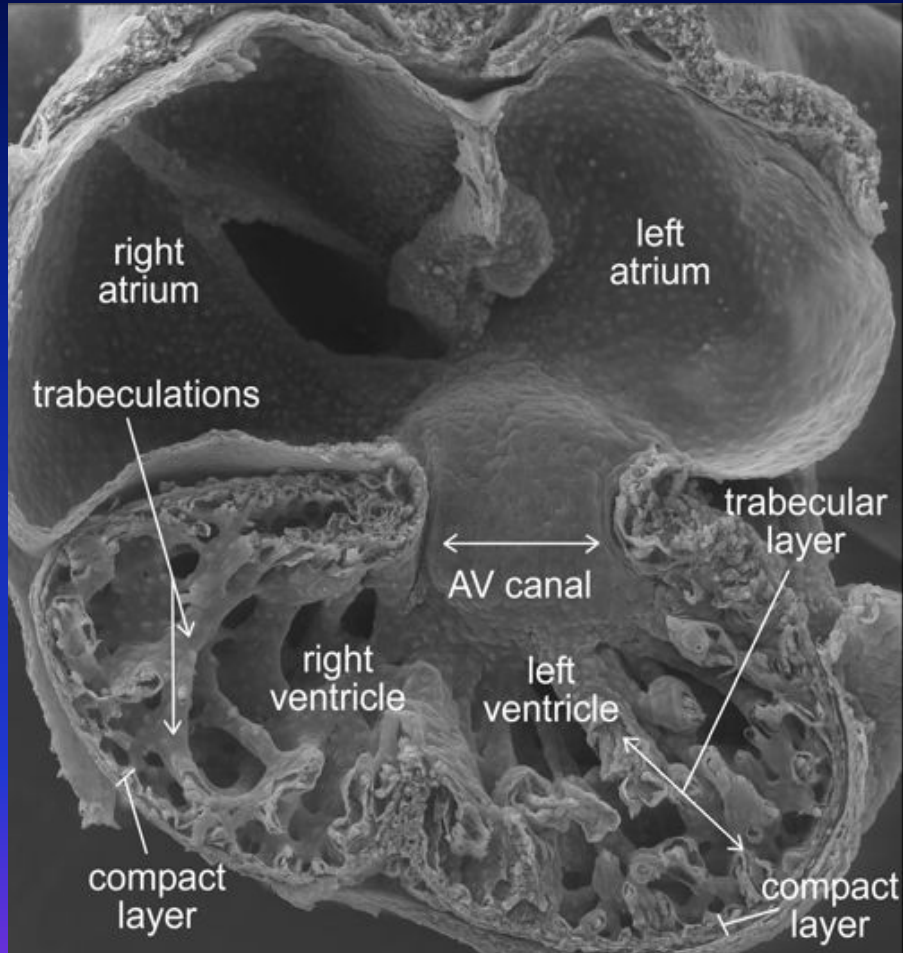
# Non-Compaction of Left Ventricle



Cross-section through cardiac ventricles of autopsy specimen.

Ratio of  $NC/C \geq 2$  is considered diagnostic of LVNC

# Presumed Cause of Non-Compaction



Embryonic Heart

Heart in LVNC

# Conditions Associated with LVNC

♥ Other congenital abnormalities may occur:

- ❖ Obstructive valve lesions
- ❖ Facial dysmorphism in children
- ❖ Neuromuscular disorders
- ❖ Ebstein's anomaly.
- ❖ WPW type pre-excitation on EKG.

# Diagnosis of LVNC

♥ Currently imaging studies are the only way to diagnose LVNC in life:

❖ Echocardiography

❖ MRI, CT scan

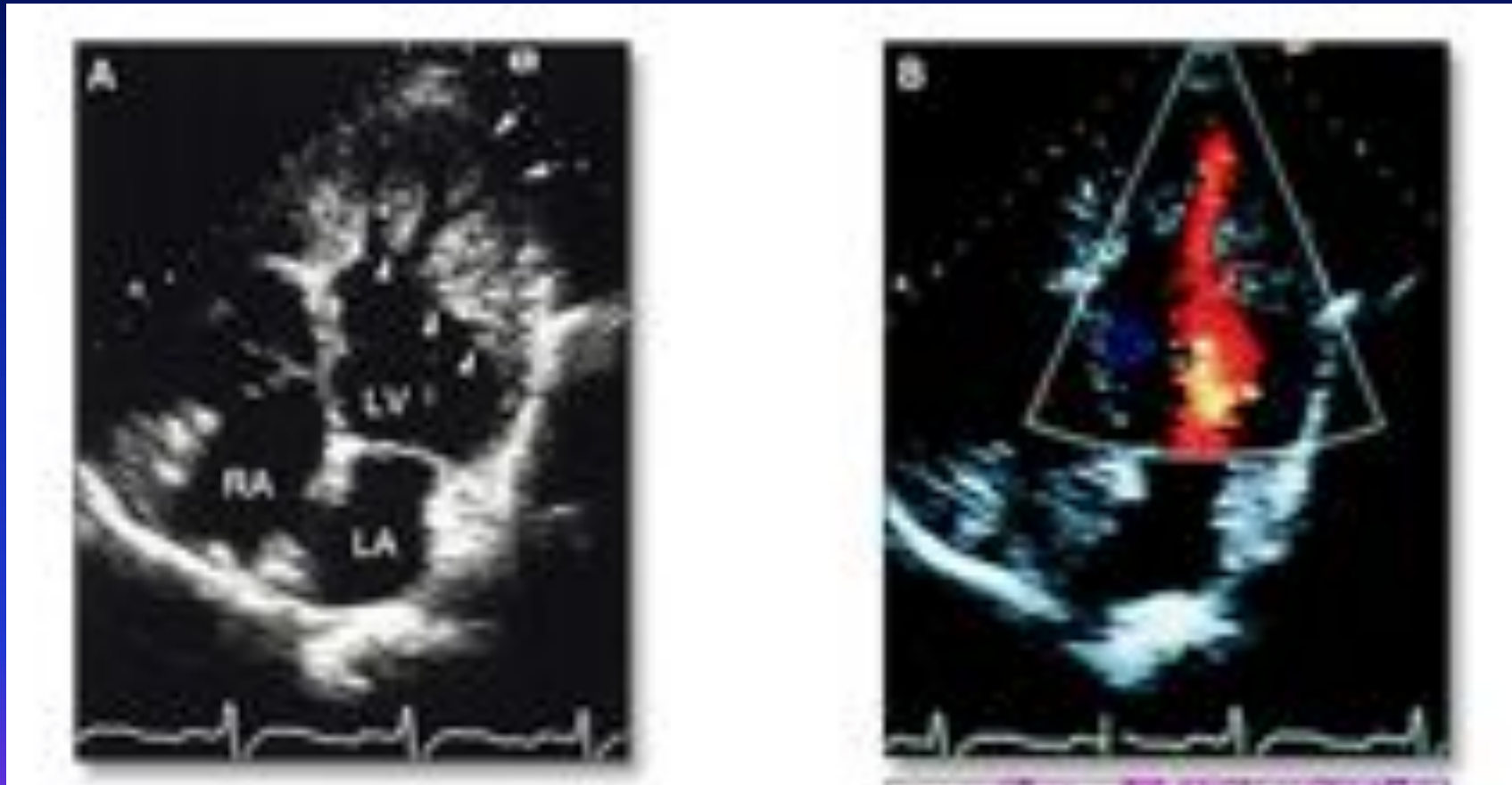
❖ Contrast Angiography

❖ Video angioscopy.

♥ At pathology examination of the explanted hearts show the excessive trabeculations

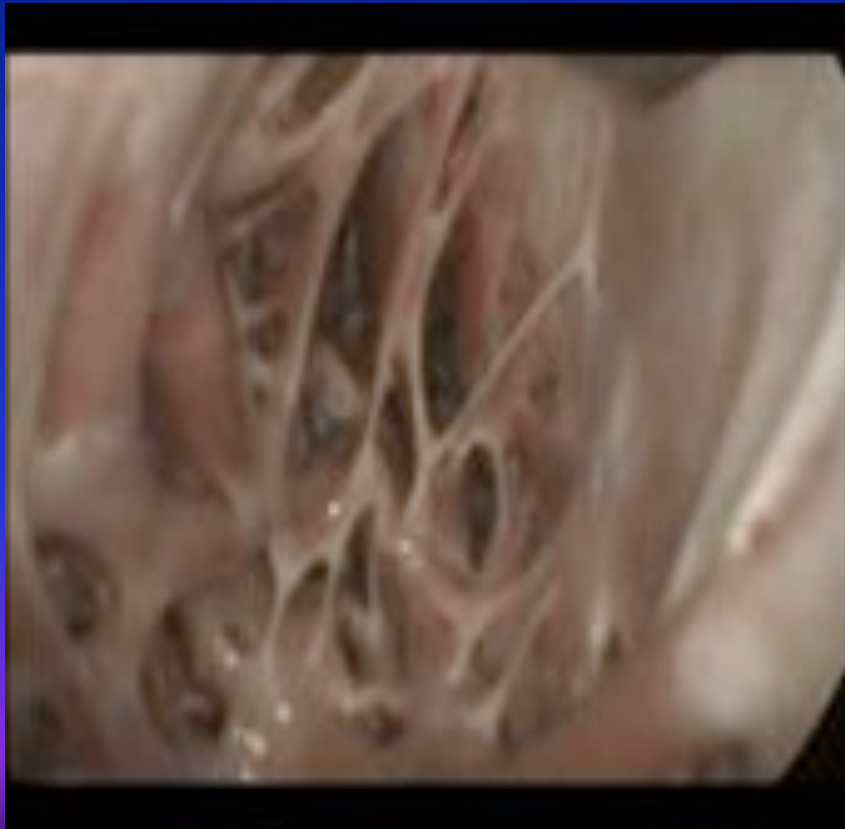
♥ At autopsy direct examination of the LV.

# Echocardiogram in LVNC

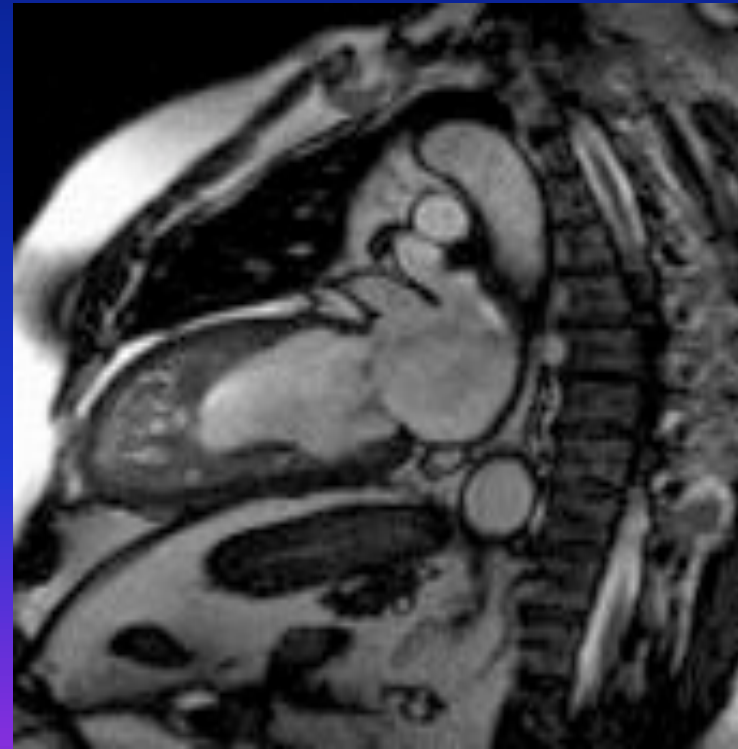


# Diagnosis of LV Noncompaction

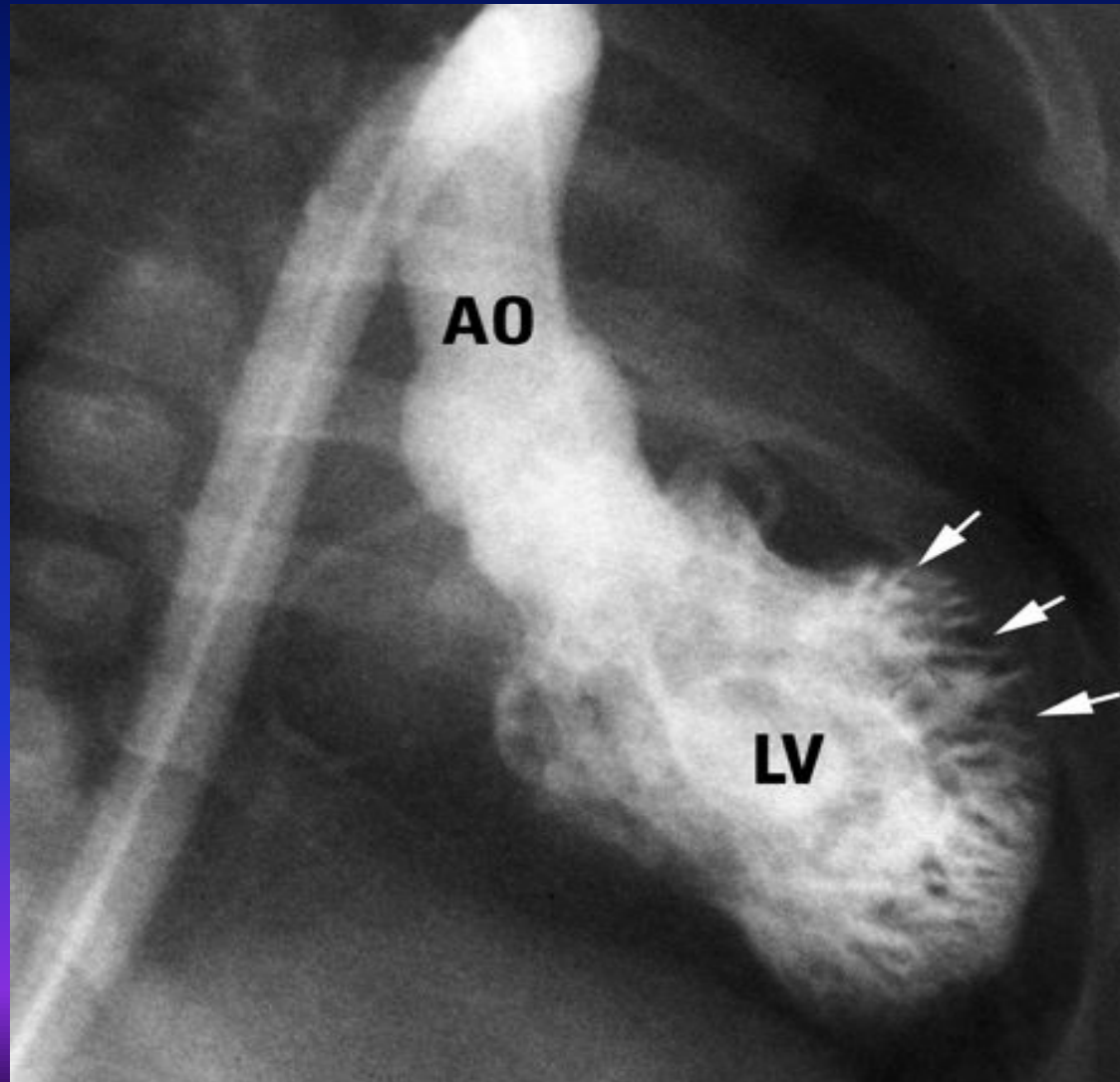
## Videoangiography



## MRI of heart with LVNC



# Contrast Angiogram of LV



# What are the complications in LVNC?

Major complications are:

## ♥ Heart failure:

- ❖ Both systolic and diastolic HF can occur.

## ♥ Arrhythmias:

- ❖ Patients may be on anti-arrhythmic medicines, have pacemakers, ICDs etc., or may have had RF ablation for atrial or ventricular arrhythmias.

## ♥ Thromboembolism:

- ❖ Both systemic and pulmonary embolism can occur.

# Pregnancy and LV Noncompaction

- ♥ Now that the treatment of many heart conditions in young women has much improved, they are likely to get pregnant and present to the gynecologists or to hospital emergency dept.
- ♥ These young women may have been on antiarrhythmic medicines, or anticoagulants and may have pacemakers and ICDs.
- ♥ Collaboration between the cardiologists, gynecologists and anesthesiologists is important.

# What happens to women with LVNC during pregnancy?

Limited literature is available on this topic.

- ♥ Women may experience no symptoms during pregnancy and may have normal childbirth.
- ♥ They may present with symptoms and signs due to the complications such as heart failure, arrhythmias or thromboembolism.
- ♥ Due to lack of widespread knowledge of this condition, even after an echocardiogram, the condition may be misdiagnosed as hypertrophic or dilated cardiomyopathy.
- ♥ At times the heart failure may be mistaken as peripartum cardiomyopathy.

**CASES WITH  
LVNC & PREGNANCY**

# LVNC Mimicking Peripartum Cardiomyopathy

## ♥ Case 1:

**26 yr. woman** with gestational HTN presented at 31 wks of pregnancy with dyspnea and dizziness.

**Past history** of preeclampsia and induction of labor at 35 wks of pregnancy; tracheo-esophageal fistula repair; frequent pneumonias in childhood.

**TTE** : LV EF <20%, Mild MR, LVNC pattern with NC/C = 3.2

At 37 wks. Labor was induced resulting in normal delivery.

**2 months after delivery she had RF ablation for recurrent atrial flutter; at the same time a ventricular tachycardia was also ablated.**

TTE : 3 months after delivery showed improved LV EF 30%.

# LVNC Mimicking Peripartum Cardiomyopathy

## ♥ Case 2:

**14 yr old girl** at 36 wks. of pregnancy, presented to ER with peripheral edema and headaches.

**Past History:** Sickle cell trait, poor wt gain & Gonorrhea. At age 9 she had HPV condyloma and a mature teratoma.

During pregnancy blood cultures were positive for gr. B strep.

Due to pulmonary edema, she was intubated in the ER and was taken for emergency C-section.

**Initial TTE:** LV EF 17%, LVID<sub>D</sub> 63 mm; typical LVNC pattern with NC/C = 1.63.

**Initial Medical Treatment:** Nesiritide, Milrinone and Dobutamine.

**F/U** at 17 months EF improved to 30%.

**Patel C: JASE 20: 1009, e9-e12, 2007**

# Peripartum Cardiomyopathy in LVNC

25 year old G2 P2 with no significant past medical history had cardiac arrest 8 wks. after a normal pregnancy and an uncomplicated delivery.

- ♥ TTE showed dilated LV and 5% EF.
- ♥ Angiography: Normal coronaries. IABP was inserted.
- ♥ TEE during LVAD placement showed LVNC pattern.
- ♥ Myocardial biopsy: Mild lymphocytic myocarditis.
- ♥ TEE during removal of LVAD 3 months later also showed LVNC.
- ♥ 6 months later EF improved to 47% by TTE.

# Familial occurrence of LVNC

- ♥ 24 year old woman with a diagnosis of dilated cardiomyopathy was referred at 5 weeks of gestation for evaluation and follow up.
- ♥ She had a miscarriage 4 months prior to this pregnancy.
- ♥ EKG showed sinus rhythm with WPW pattern and her BNP was elevated. TTE showed EF 45% and typical LVNC.
- ♥ At 31 weeks she had increasing PASP and BNP and an elective cesarean section was performed under general anesthesia.
- ♥ Echocardiographic screening of her baby and also her mother showed LVNC, and her mother also had WPW on EKG.

# Familial occurrence of LVNC

- ♥ A nulliparous woman at 24 weeks of gestation was referred for dyspnea and fetal hydrops.
- ♥ Echocardiogram of mother showed typical two layered structure of LVNC and depressed LV systolic function. Fetal echo showed cardiomegaly.
- ♥ Emergency cesarean section was performed due to maternal HF.
- ♥ On second day the neonate died and autopsy confirmed LVNC.

## Pregnancy after ICD in LVNC

♥ Kobza et al reported one woman with LVNC who became pregnant 33 months after an ICD placement and delivered a healthy baby by Cesarean section. During the pregnancy no tachyarrhythmias were registered by the ICD.

## Pregnancy with LVNC and ICD for Postpartum Sustained V.T.

- ♥ 28 yr female 3<sup>rd</sup> pregnancy at 22 weeks, presented with palpitations and SOB for 3 weeks..
- ♥ Two previous pregnancies were uncomplicated.
- ♥ TTE: All 4 chamber dilatation and LVNC pattern; severe MR; estimated PAP 64/15 mmHg.
- ♥ Medically managed until 36 wks and delivered a healthy baby by elective Cesarean Section.
- ♥ 10 days after delivery she had sustained monomorphic VT and received an ICD.
- ♥ F/U at 6 months she was in NYHA class II

Williams, RI et al JASE 16: 293-296, 2003

# ANESTHETIC MANAGEMENT

## Anesthetic Management of C-Section in Pregnant patients with LVNC

- ♥ 1st pregnancy: patient in symptomatic heart failure:
- ♥ At 24 weeks of pregnancy C-section was carried out using propofol and fentanyl with stable intraoperative hemodynamics.
- ♥ 2 years later patient was pregnant again. On medical therapy she had normal cardiac function and was not on anticoagulants.
- ♥ At 34 weeks C-section was carried out under spinal anesthesia.
- ♥ Both peri-operative courses were uneventful.

## Anesthetic Considerations for C-section in patients with ICDs

- ♥ General or epidural anesthesia is used commonly.
- ♥ Epidural anesthesia offers some advantages :
  - ❖ Easy conversion from labor analgesia to surgical anesthesia.
  - ❖ Preservation of fetal and maternal hemodynamics.
  - ❖ Prevention of increase in catecholamines.
  - ❖ Possible suppression of arrhythmias due to pharmacologically-active plasma levels of local anesthetic.
- ♥ Turning the ICD off or on did not seem to affect the outcome in one study. If electrocautery is to be used ICDs are turned off.


# Summary


- ♥ LVNC has a distinct morphology and is classified as a genetically mediated cardiomyopathy.
- ♥ Pregnancy is not uncommon in patients with isolated LVNC. Very little published literature is available on this topic.
- ♥ Diagnosis may be missed if the physicians are unaware of this condition.
- ♥ Management is same as for complications occurring in patients with other cardiac conditions.
- ♥ Family screening is important to detect this genetically mediated cardiomyopathy in the new born as well as other family members.


Pregnancy is like a prolonged stress test with child birth as the peak stress.


With good cardiac reserve the outcome is expected to be good but we need more studies.


*Thank you for your attention*











# L.V. Noncompaction - Background

---

- ♥ 1932: 1<sup>st</sup> description of LV Hypertrabeculation in a newborn with Congenital Heart Disease.
- ♥ 1984: 1<sup>st</sup> case report of isolated “persistent LV myocardial sinusoids”
- ♥ 1985: 1<sup>st</sup> echocardiographic and angiographic description published in German Radiology Journal.
- ♥ 1986: 1<sup>st</sup> post-mortem confirmation of imaging findings.
- ♥ 1995: Categorized as unclassified cardiomyopathy by WHO.
- ♥ 1996: 1<sup>st</sup> Ten year observational study of 17 adults with LVNC.